

# Histological study of the respiratory system of Sulawesi Medaka fish (*Oryzias celebensis*): as a candidate of animal model

Dwi Kesuma Sari<sup>1\*</sup>, Irma Andriani<sup>2</sup>, Khusnul Yakin<sup>3</sup>

<sup>1</sup>*Study Program of Veterinary Medicine, Faculty of Medicine, Hasanuddin University, Jl. Perintis kemerdekaan Km. 10, Makassar, South Sulawesi*

<sup>2</sup>*Study Program of Biology, Faculty of Mathematics and Natural Sciences, Hasanuddin University*

<sup>3</sup>*Faculty of Marine Sciences and Fisheries, Hasanuddin University*

\*Correspondence: [dwiks73@gmail.com](mailto:dwiks73@gmail.com), [dwiksari@vet.unhas.ac.id](mailto:dwiksari@vet.unhas.ac.id)

**Abstract.** Sulawesi medaka fish (*Oryzias celebensis*) is a type of medaka fish that are endemic in the region of South Sulawesi. The use of medaka fish as a candidate animal model has been started which has similarities with the Zebra fish that was first developed as an animal model. This research aims to study the histology of the respiratory system in Sulawesi medaka fish. Histological observation on the respiratory system of Sulawesi medaka fish using gills organ. Histological observation showed that the gills have afferent arterioles at the end of the primary lamellae and efferent arterioles at the bottom of primary lamellae. The epithelial cell layer along the surface of the lamella, chloride cells and mucous cells among the base of secondary lamellae, cartilage at the base of the primary lamellae, venous sinus along the primary lamellae which is forwarded to the secondary lamellae through the capillaries and pillars cells in the secondary lamellae. In general the structure of the respiratory system in Sulawesi medaka fish similar with Zebra fish as well as other Teleostei fish.

Key words: Sulawesi medaka fish, respiratory system, gills, animal model

## Introduction

Fish medaka (*Oryzias* sp) is a fish that has several advantages as an experimental animal that is easy to nurseries, the reproductive cycle is short (maturation initial 2 months), embryos are transparent, the generation time is short, the genome size is small and has had a construction of transgenic (Naruse *et al.*, 1985; Denny *et al.*, 1998; Ishikawa, 2000). Some biological information to the molecular systematics of medaka fish, especially the Japanese medaka fish (*Oryzias latipes*) is also widely found (Andriani and Hassan, 2013; Takehana *et al.*, 2015). Needs medaka fish as an animal model has made researchers using medaka fish as animals test to create a wide variety of strains of medaka fish *Oryzias latipes*. But in Indonesia as a distribution center of medaka fish species, information about particular medaka fish endemic to Sulawesi Island as *Oryzias celebensis* still very poor and have not been domesticated as well as to be further explored. Medaka fish as well as Zebra fish have started to be used as experimental animals. Some mutant medaka fish species have also been made for screening diabetes drugs, cancer, especially skin cancer and other degenerative diseases.

Medaka (*Oryzias* sp) including a group of small fish on the taxonomic belonging to the family Adrianichthyidae (Kottelat *et al.*, 1993; Nelson, 2006). The distribution of these fish covering a wide area from India to Japan and South along the islands of the Indo-

Australian in the Wallacea line, namely Timor and Sulawesi (Moss and Wilson, 1998; Parenti, 2008). The discovery of the new species of medaka fish species is also increasing (Parenti and Soeroto, 2004, Parenti *et al.*, 2013)). From exploration results the researchers showed that Sulawesi has a particularly high endemism of the fish family Adrianichthyidae. The high endemism is not only supported by the restrictions zoogeography as the island and the line of Wallacea Weber, but also because this is not a group of fish traded so the chances for migration very limited. These facts underlying the statements by some researchers that medaka fish can unravel the mystery of the evolution of the marine fauna that exist in Sulawesi

As development of Sulawesi medaka fish (*Oryzias celebensis*) as an animal model and in an effort to use Sulawesi medaka fish in the field of histology and pathology, research has been done of the respiratory system in Sulawesi medaka fish. The results of this study are expected to be the gateway for the development of medaka fish as an animal model.

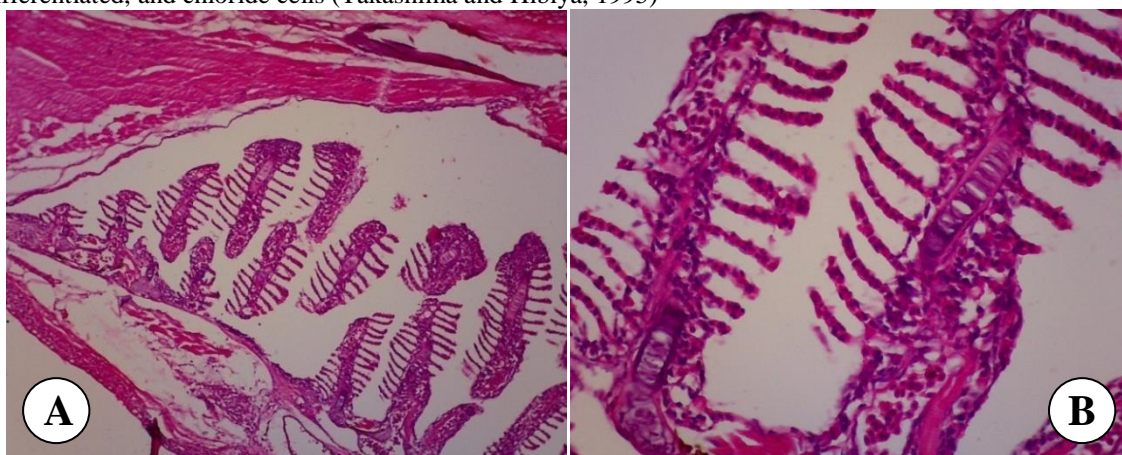
This research aims to develop medaka fish as an animal model through histological observation, especially on the observation of the respiratory system of Sulawesi medaka fish.

### Matherials and Methods

The samples of Sulawesi medaka fish about six adult fishes with average of size and weight. Sulawesi medaka fish were obtained from Rammang-Rammang Maros South Sulawesi. The fishes and then kept in aquariums for temporary before sampling. Fish samples stored in 10% formalin p.a. The Sulawesi medaka fish sizes are small and the observations made by one part of the body of the fish. The fishes are processed in the process of further histotechnique (Kiernan, 1990). Samples were dehydrated with graded series alcohol and clearing using xylol before embedding with paraffin. The tissues were then cut using microtome with 4  $\mu\text{m}$  thickness, then samples were stained using Mayer's Hematoxylin eosin (HE) (Kiernan, 1990).

### Results and Discussions

Observations were made under a microscope which has been connected to the camera microscope (Olympus 22x with advanced Optilab). Histological preparations of gills of Sulawesi medaka fish were observed. Sections were observed the lamellae of gill consisting of primary lamellae and secondary lamellae, lacuna and its constituent cells as the pillars cells, epithelial cells, mucous cells, cells that have not differentiated, and chloride cells (Takashima and Hibiya, 1995)



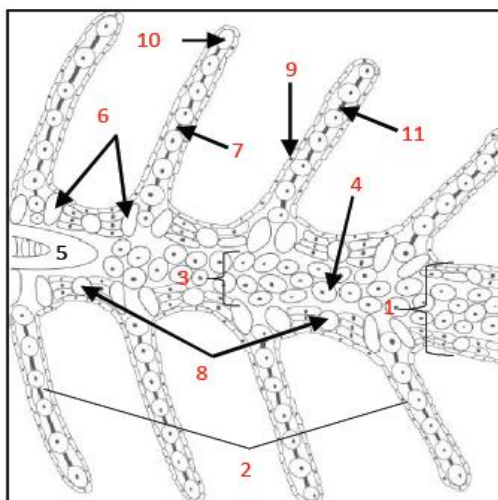


Figure. Histology of the gills of Sulawesi medaka fish, sagittal section, A: 100x and B: 400x and the schetch (based on Pinontoan *et al.*, 2016)

1. primary lamellae; 2. secondary lamellae; 3. venous sinus;
4. erythrocyte in venous sinus;
5. cartilage; 6. chloride cells;
7. pillars cells; 8. mucous cells; 9. epithelial cells;
10. erythrocyte in capillary lumen 11. lacuna

Sulawesi medaka fish has afferent arterioles at the base of the primary lamellae and efferent arterioles at the end of the primary lamellae. There is a cartilage in the primary lamellae. Mucus cells at the primary lamellae located between the base of each secondary lamellae. Chloride cells located in the right at the base of the secondary lamellae. The cells associated with the respiratory system were erythrocytes in every part of the lamella, the erythrocytes in the primary lamellae flowing in the veins as well as venous sinuses that connect the afferent arterioles and located at the base of the primary lamellae and arterial efferent located at the end of the primary lamellae and the secondary lamellae contained the lumen of the capillaries that contained erythrocyte, pillar cells and then the outer part is covered by epithelial cells (Figure A and B).

The gills play an important role in the oxygenation of the blood (Takashima and Hibiya, 1995). Water is passed in, through the mouth, over the gills and out through the operculum. The waterflow is driven by alternate expansion and contraction of the buccal and operculum chambers. Blood flows via the afferent filament arteries of the primary lamellae into the blood spaces of the secondary lamellae, where CO<sub>2</sub> is released into the water and O<sub>2</sub> is taken up. In Zebra fish, the secondary lamellae consist of one layer of epithelial cells, supported, and separated, by pillar cells (Menke *et al.*, 2011). The oxygenated blood leaves the secondary lamellae by efferent lamellar arteries to feed the dorsal aorta, from where it is distributed to all tissues. The histological features of the gills of Sulawesi medaka fish almost same with Zebra fish as well as Teleostei in general. In addition to their role in the oxygenation of blood, the gills also play an important role in acid-base balance, osmoregulation, and the excretion of waste products.

## Conclusions

Based on the results of this study concluded that Sulawesi Medaka fish using gill as a major respiratory organ. Histological structure of the gills of Sulawesi medaka fish same as Teleostei fish in general. The gills consisted of the primary lamellae and secondary lamellae and containing mucous cells, chloride cells, cartilage on the basis of primary lamellae, columns cells, pillar cells and erythrocytes that exist along the capillary and venous sinus.

## Acknowledgments

Researchers thanks to Annita Vury N. and Andi Resky Muwardani for helping the research and in particular to the National Grant Scheme Competence of the Ministry of Research Technology and Higher Education Batch No. 019 / SP2H / LT / DRPM / II / 2016

## References

1. Andriani I, Hassan M. 2013. Morphological characteristic and isolation of germ cell : a preliminary study for the germ cell transplantation of celebes rainbow (*Marosatherina ladigesii*). Proceeding pada 2<sup>nd</sup> International Seminar of Fish and Marine Universitas Riau, Pekanbaru.
2. Denny, JS., Robert L. Sephar, Kurt E. Mead, dan Shirin C. Yousuff. 1991. Guidelines for Culturing The Japanese Medaka *Oryzias latipes*. US Environmental Protection Agency. Environmental Research Laboratory-Duluth. Office of Research and Development. Duluth Minnesota 55804.
3. Kiernan, JA. 1990. Histological and histochemical methods : theory and practice. Pergamon Press, Toronto.
4. Kinoshita, M., Murata, K., Naruse, K. Tanaka, M. 2009. Medaka. Biology, Management and Experimental Protocols. Wiley-Blackwell Publishing. Iowa USA. 419 + XXI pp.
5. Kottelat, M., Whitten A.J., Kartikasari S.N and Wiriatmojo, S. 1993. Freshwater fishes of western Indoensia and Sulawesi. Periplus edition (HK) Ltd and EMDI Project. Republik Indonesia.
6. Menke, AL., Spitsbergen, JM., Wolterbeek, APM., Woutersen, RA. 2011. Normal anatomy and histology of the adult Zebrafish. *Toxicologic Pathology*, 39: 759-775
7. Moss SJ, Wilson MEJ (1998) Biogeographic implications of the Tertiary palaeogeographic evolution of Sulawesi and Borneo. *Backbuys, Leiden*, (pp) 133-163.
8. Naruse K, Ijiri K, Shima A, Egami N. 1985. The production of cloned fish in the medaka (*Oryzias latipes*) *J.Exp.Zool.*236(3):335-41
9. Nelson JS (2006) *Fishes of the World*, fourth ed. Wiley, New York
10. Parenti LR, Soeroto B (2004) *Adrianichthys roseni* and *Oryzias nebulosus*, two new ricefishes (Atherinomorpha: Beloniformes: Adrianichthyidae) from Lake Poso, Sulawesi, Indonesia. *Ichthyol Res* 51: 10-19.
11. Parenti LR (2008) A phylogenetic analysis and taxonomic revision of ricefishes, *Oryzias* and relatives (Beloniformes, Adrianichthyidae). *Zool J Linn Soc* 154: 494-610.
12. Parenti, Lynner R., Renny K. Hadiaty, Daniel Lumbantobing dan Fabian Herder. 2013. Two New Ricefishes of the Genus *Oryzias* (Atherinomorpha: Beloniformes: Adrianichthyidae) Augment the Endemic Freshwater Fish Fauna of Southeastern Sulawesi, Indonesia. *Copeia* 2013 (3): 403-414.2013.
13. Pinontoan, AA., Sari DK., Wahyuni. 2016. Anatomy and histological study of the gills of Bungo fish (*Glossogobius sp.*). In preparation
14. Takashima, F and Hibiya, T. 1995. An atlas of fish histology. Normal and pathological features. Second edition. Kodansha Ltd, Tokyo, Japan.
15. Takehana Y, Naruse K, Sakaizumi M. 2005. Molecular phylogeny of the medaka fishes genus *Oryzias* (Beloniformes: Adrianichthyidae) based on nuclear and mitochondrial DNA sequences. *Mol Phylogenet Evol.* 36(2):417-28.